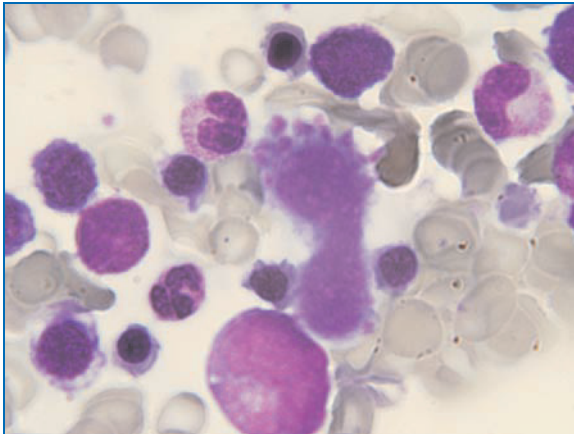


SNAPSHOT

Steps to recovery

This bone marrow smear was taken from a child after chemotherapy for acute lymphoblastic leukaemia. The marrow showed no residual leukaemia, and provided this photographic evidence of her steps towards remission.



Annmarie A Bosco*
Giselle Kidson-Gerber*

*Haematology Registrar
South Eastern Area
Laboratory Services
Randwick, NSW
boscoa@sesahs.nsw.gov.au