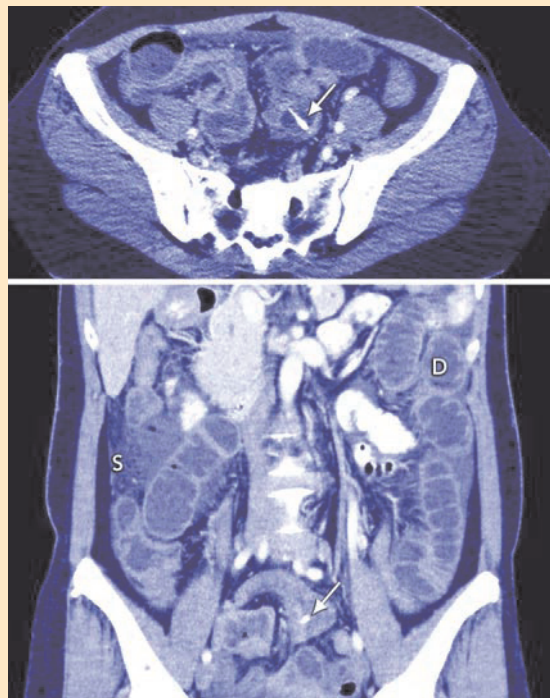


SNAPSHOT

Impacted fishbone in Meckel diverticulum



A 51-year-old woman presented with a 2-day history of left iliac fossa pain. Axial and coronal computed tomography images (Figures) revealed a linear intraluminal foreign body (arrows) impacted in the wall of a blind-ended loop of small bowel over the midline, consistent with a fishbone in a Meckel diverticulum. Small bowel dilatation due to ileus (D) and inflammatory stranding in the peritoneal fat (S) were also present. Surgery revealed pinpoint bowel perforation caused by a 2cm long fishbone, from *Pampus argenteus* (silver pomfret), in a 5cm long Meckel diverticulum.

Uei Pua, Radiologist
Tan Tock Seng Hospital, Singapore.
druei@yahoo.com

□