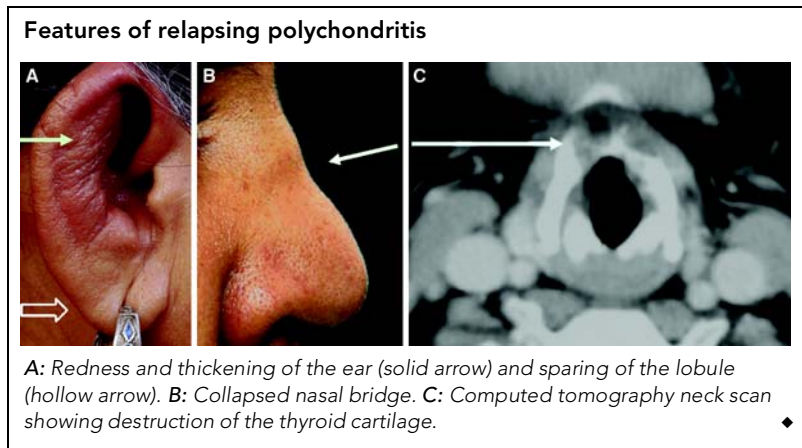


A woman with abnormal ears and an unusual voice



A 47-year-old woman presented with a 6-month history of fever, redness and pain in her ears and nose, and hoarseness of voice. She had redness and thickening of both ears (Figure A, solid arrow) with sparing of the lobule (hollow arrow), and a collapsed nasal bridge (Figure B). A computed tomography neck scan revealed destruction of the thyroid cartilage (Figure C). Antineutrophil cytoplasmic antibodies were negative, ruling out Wegener's granulomatosis.

A diagnosis of relapsing polychondritis was made, and prednisolone and azathioprine were commenced. After 7 months of follow-up, there have been no further episodes of cartilagenous inflammation.

Aman Sharma, MD, Assistant Professor, Internal Medicine
Pradeep Bamberg, MD, FRCP(Glas), Professor, Internal Medicine
Ajay Wanchu, MD, DM, Additional Professor, Internal Medicine
Surjit Singh, MD, Professor, Internal Medicine
Naresh K Panda, MS, FRCS(Edin), Professor, Otolaryngology
 Postgraduate Institute of Medical Education and Research (PGIMER),
 Chandigarh, India.
 amansharma74@yahoo.com □