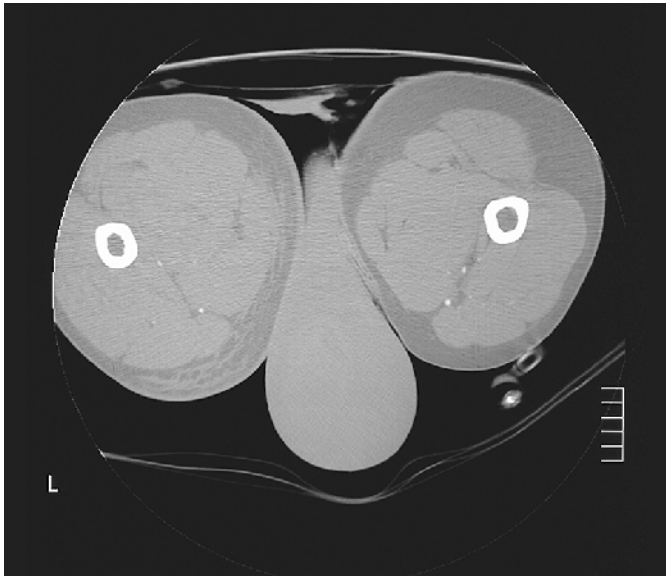


### Cartoon face

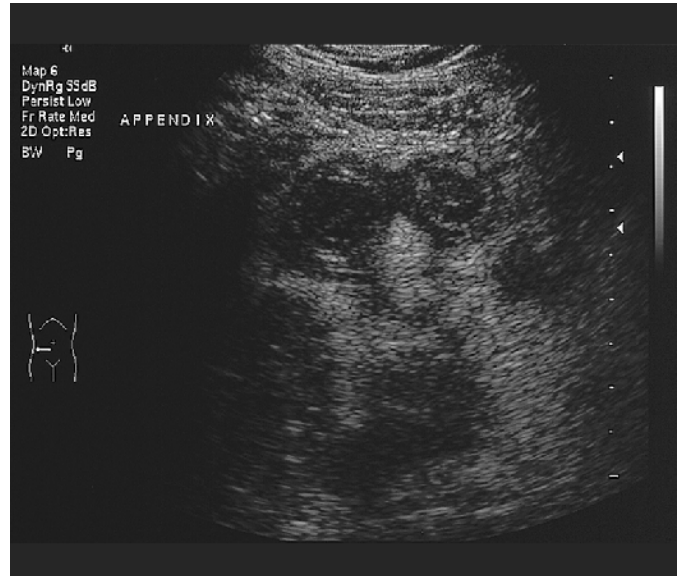

This cheerful “Kilroy was here” image is a CT scan showing the grossly swollen scrotum of a young man after a motor bike accident.

**Bit Lock Wong**

Radiology Registrar  
Department of Radiology, Liverpool Hospital, Liverpool, NSW

### A cute appendicitis

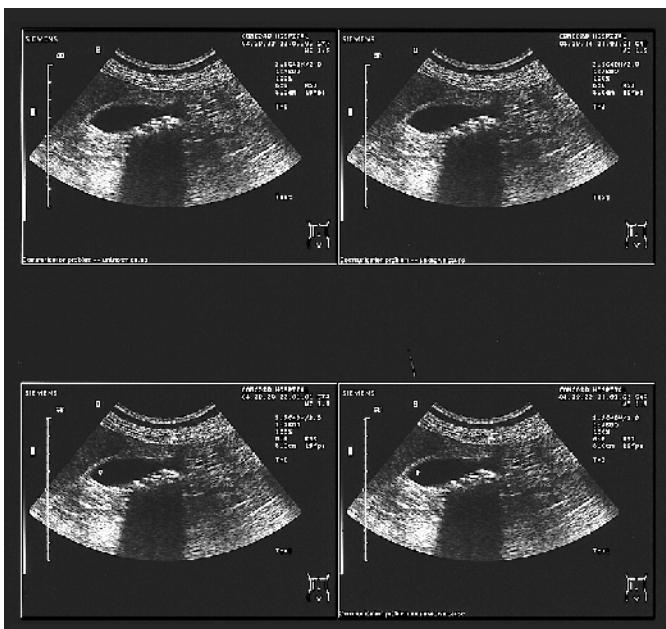


An abdominal ultrasound of a patient with right iliac fossa pain revealed the culprit, smiling cheekily.

**Khimseng Tew**

Radiology Registrar  
The Queen Elizabeth Hospital, Adelaide, SA

### Fishy gallbladder

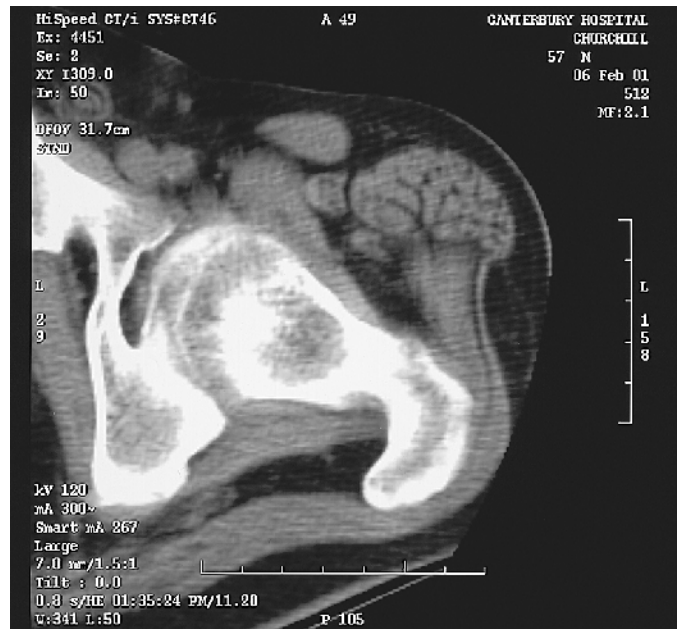

When the patient presented with colicky abdominal pain we smelt something fishy. Abdominal ultrasound confirmed the diagnosis.

**Nishantha S Karunaratne**

Radiology Registrar  
Concord Repatriation General Hospital, Concord West, NSW

### Brain in the left thigh



*Fetus in fetu* is a known phenomenon; could this be one? Or neural tissue in a dermoid cyst? Whatever, the patient appears well endowed, with the CT scan showing a spare brain and spinal cord in the thigh muscles.

**Rodney H Strahan**

Radiologist  
Austin & Repatriation Medical Centre, Heidelberg, VIC