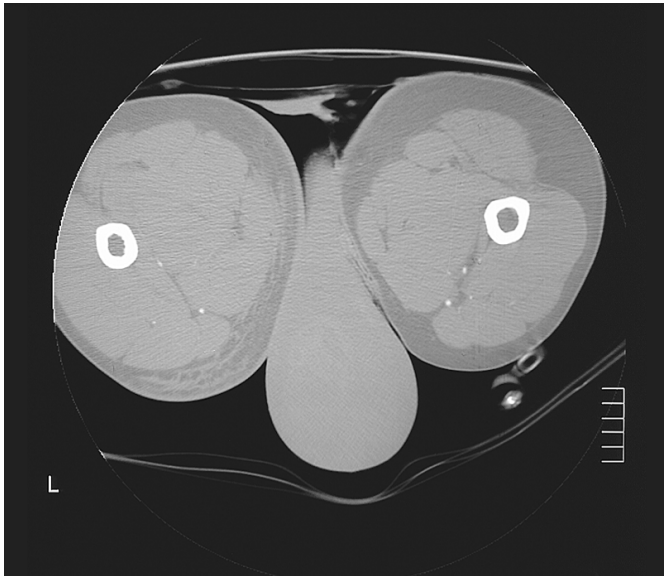


Cartoon face

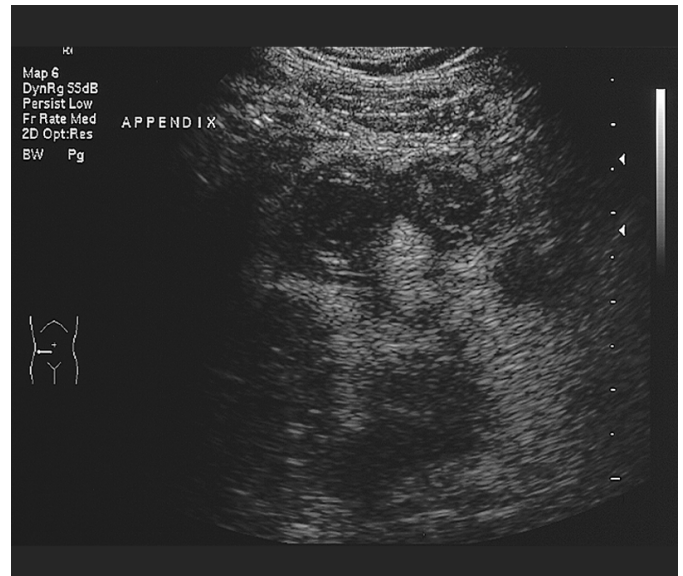

This cheerful “Kilroy was here” image is a CT scan showing the grossly swollen scrotum of a young man after a motor bike accident.

Bit Lock Wong

Radiology Registrar
Department of Radiology, Liverpool Hospital, Liverpool, NSW

A cute appendicitis

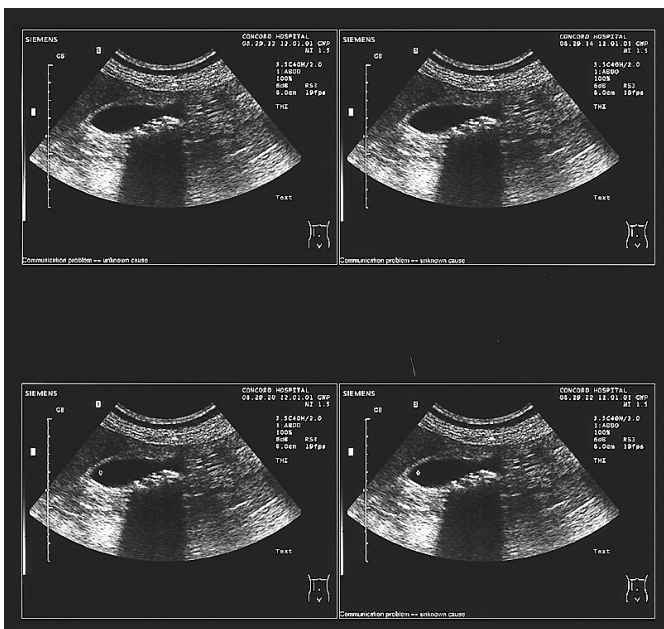


An abdominal ultrasound of a patient with right iliac fossa pain revealed the culprit, smiling cheekily.

Khimseng Tew

Radiology Registrar
The Queen Elizabeth Hospital, Adelaide, SA

Fishy gallbladder

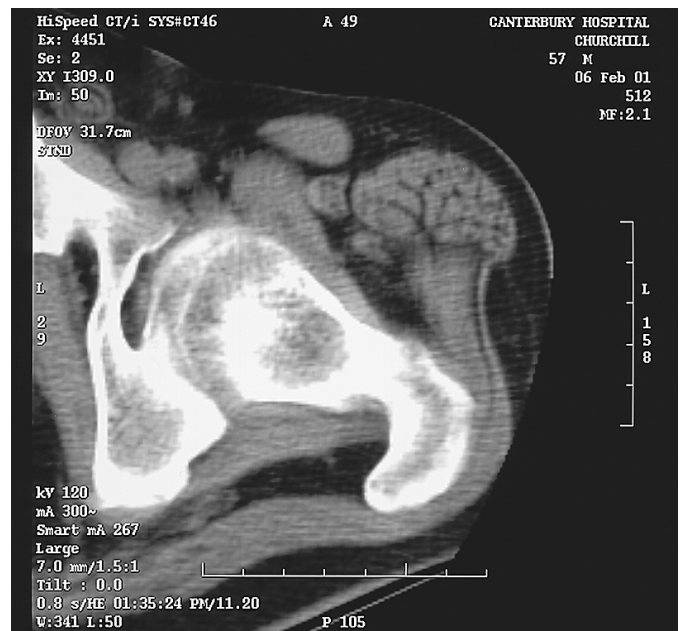

When the patient presented with colicky abdominal pain we smelt something fishy. Abdominal ultrasound confirmed the diagnosis.

Nishantha S Karunaratne

Radiology Registrar
Concord Repatriation General Hospital, Concord West, NSW

Brain in the left thigh



Fetus in fetu is a known phenomenon; could this be one? Or neural tissue in a dermoid cyst? Whatever, the patient appears well endowed, with the CT scan showing a spare brain and spinal cord in the thigh muscles.

Rodney H Strahan

Radiologist
Austin & Repatriation Medical Centre, Heidelberg, VIC