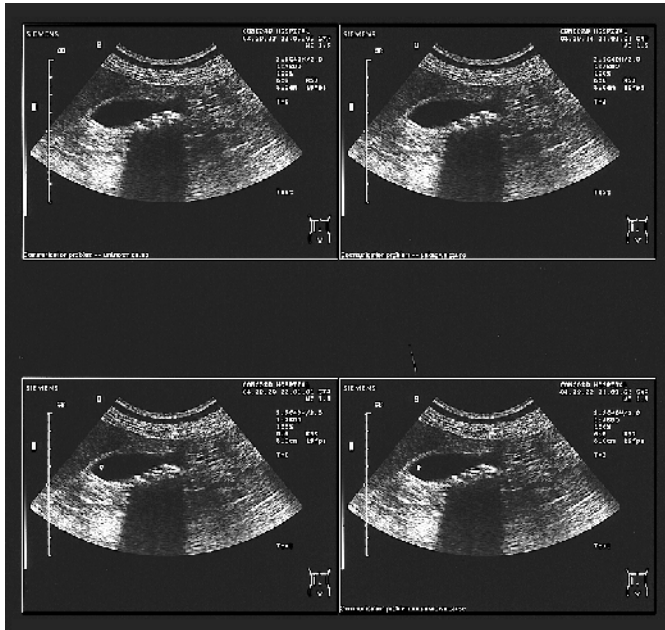


Fishy gallbladder

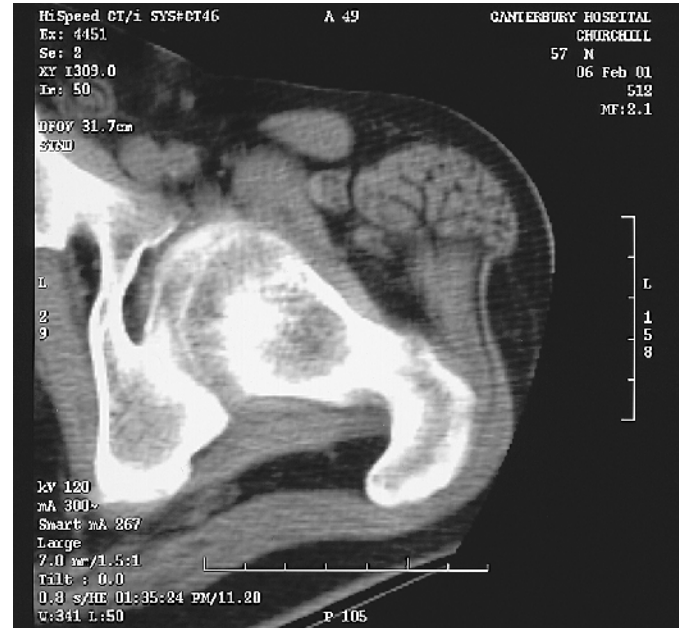

When the patient presented with colicky abdominal pain we smelt something fishy. Abdominal ultrasound confirmed the diagnosis.

Nishantha S Karunaratne

Radiology Registrar
Concord Repatriation General Hospital, Concord West, NSW

Brain in the left thigh



Fetus in fetu is a known phenomenon; could this be one? Or neural tissue in a dermoid cyst? Whatever, the patient appears well endowed, with the CT scan showing a spare brain and spinal cord in the thigh muscles.

Rodney H Strahan

Radiologist
Austin & Repatriation Medical Centre, Heidelberg, VIC