

The first known ChAdOx1 nCoV-19 vaccine-induced thrombotic thrombocytopenia in Australia

Jay Hocking
Box Hill Hospital
Department of Haematology
Box Hill, Victoria, Australia

Sanjeev Daya Chunilal
Unit Head Laboratory Haematology
Monash Health
Department of Haematology
Monash Medical Centre
Clayton, Victoria, Australia

Vivien Chen
Concord Hospital
Department of Haematology
Concord, New South Wales, Australia

Tim Brighton
Prince of Wales Hospital and Community Health Services
Department of Haematology
Randwick, New South Wales, Australia

James Nguyen
Box Hill Hospital
Department of Haematology
Box Hill, Victoria, Australia

Joycelyn Tan
Box Hill Hospital
Department of Haematology
Box Hill, Victoria, Australia

Stephen B N Ting
Director of Clinical Haematology
Eastern Health
Department of Haematology
Box Hill, Victoria, Australia

Huyen Tran
Head, Haemostasis Thrombosis Unit
Alfred Hospital
Department of Clinical Haematology
Melbourne, Victoria, Australia

Professor
Monash University Central Clinical School
Department of Clinical Haematology
Australian Centre for Blood Diseases
Melbourne, Victoria, Australia

Competing interests: No relevant disclosures

Introduction

In March 2021, Australia began the roll out of the ChAdOx1 nCoV-19 vaccine to combat the COVID-19 pandemic. In Europe where more than 20 million doses of this vaccine had been administered by mid-March 2021, case reports of thrombosis at unusual sites associated with thrombocytopenia, occurring day 4 to 28 post vaccination with a mortality rate of up to 25%, at an estimated rate of 1:100,000 were being received (1).

In Australia, ChAdOx1 nCoV-19 vaccine was initially offered to highest-at-risk professions without age restriction. By the end of March 2021, approximately 350,000 first dose of ChAdOx1 nCoV-19 vaccine had been administered Australia wide. Here we report the first known Australasian case of ChAdOx1 nCoV-19 vaccine-induced thrombotic thrombocytopenia (VITT).

Case report

Clinical record

A 44-year-old male health care worker presented with fevers, fatigue, head “fogginess” with abdominal discomfort and increased bowel frequency eight days after receiving his first dose of the ChAdOx1 nCoV-19 vaccine. He was previously well with a past history of depression, and only taking escitalopram. He had no prior thrombosis or exposure to heparin. The low platelet count, $70 \times 10^9/L$ (RR, $150-400 \times 10^9/L$) and markedly elevated D-dimer 114 mg/L (ULN, 0.5) with vague abdominal pains prompted a CT-venogram of the abdomen that demonstrated thrombosis with complete occlusion of the portal and splenic veins, and protrusion of a tongue of thrombus into the superior mesenteric vein (SMV) (Figure 1). CT-venogram of the head did not show central venous sinus thrombosis.

The rest of the full blood count and the blood film showed no microangiopathic features. The prothrombin time, activated partial thromboplastin and fibrinogen levels, liver and renal function tests were all normal. Antiphospholipid antibodies were negative and heterozygous prothrombin G20210A mutation identified. Antibodies to the SARS-CoV-2 nucleocapsid protein and COVID-respiratory PCR were negative ruling out active COVID-19 infection as a potential thrombosis aetiology.

Antibodies to the heparin platelet factor 4 (PF4) complex in patient plasma was strongly positive (OD 1.94) by ELISA (Asserachrom™ HPIA IgG). Three functional assays, including serotonin release assay (SRA, Hidex 300 SL™), MEA (Roche diagnostics™) and flow cytometry (BD Fortessa, procoagulant assay) all detected heparin-independent platelet-factor 4 (PF4) antibody complexes that activated donor platelets (2).

Management

Immediate anticoagulation was started with the anti-FXa agent, fondaparinux 10 mg (weight: 105kg) subcutaneously 24 hourly and intravenous Immunoglobulin (IVIG), 1 g/kg administered on days two and three, and repeated days seven and eight post admission. Despite achieving an anti-FXa fondaparinux level 6 hours post dose of 0.94U/mL (target

range 0.50 – 1.20), the platelets remained between 6-20 x 10⁹/L for the initial six days. The patient subsequently developed an acute abdomen clinically and a repeat CT scan showed extension and occlusive thrombus into the SMV with venous outlet obstruction and bowel ischaemic features. He underwent an immediate laparotomy with resection of 1.8 m of ischaemic bowel. Contemporaneously, given clot extension had occurred on fondaparinux, anticoagulation was changed to thrombin inhibitor, bivalirudin where its short half-life (25 minutes) allowed for titratable perioperative anticoagulation and an intravenous pulse of methylprednisolone 1g administered to augment PF4 antibody immunosuppression.

The patient returned to theatre 48h later where further compromised bowel was resected. Methylprednisolone 1g daily was reinstated for four days with an immediate platelet peak s to 385 x10⁹/L at completion of this four-day pulse. To date he is recovering well without further complications. He has transitioned to warfarin to be continued and monitored in haematology outpatients. Figure 2 summarises the time course of treatment and response.

Discussion

This is the first reported case of thrombosis at an unusual site with thrombocytopenia following ChAdOx1 nCoV-19 vaccination in Australia. The temporal association, the detection of anti-PF4 antibodies with platelet activation in absence of heparin which is neutralised at high-dose heparin is consistent with the most recent reports (3). This entity, currently labelled as VITT has pathologic similarity to autoimmune Heparin induced Thrombocytopenia (HIT) –but without prior heparin exposure. More evidence is needed to demonstrate if the serum of VITT patients, contain antibodies that can bind to PF4 independent of heparin, following vaccination against COVID-19. Further, the mechanism responsible for profound platelet activation following ChAdOx1 nCoV-19 vaccination as evidenced by ELISA high optical densities remains to be established (3). To the best of our current knowledge, there are no reported VITT cases with m-RNA COVID-19 vaccines.

It is doctrine in the management of HIT that in addition to immediate cessation of all heparins, a non-heparin anticoagulant is commenced to prevent (further) thrombosis Given the pathogenic similarities of VITT cases to HIT, we initially used fondaparinux as our patient at presentation was clinically stable with normal renal function. It is unclear if the clinical deterioration in our patient despite achieving favourable therapeutic fondaparinux drug level was resultant of anti-Xa drug(s) non-efficacy and/or because of the severity of venous outflow obstruction with compromised ischaemic small bowel. In principle, the surgical removal of any ischaemic tissue would be associated with clinical improvement.

The benefit of IVIG remains debatable but *in vitro* spiking experiments and observation of platelet increment after its administration suggests that there may be a role (3, 4). It is possible that IVIG displaces the binding of anti-PF4 antibody complex to FcγRIIA receptors on platelets (5). In our case, it is difficult to ascribe a specific clinical and platelet recovery to IVIG solely given the simultaneous timing of surgical removal of ischaemic intestine, the commencement of alternate anticoagulation with bivalirudin and pulsed high dose steroids. It is noted that pulsed methylprednisolone was prescribed in the majority of recently reported cases (3).

In line with evolving guidance documents, clinicians assessing patients who present with organ-specific thrombotic symptoms, 4 to 28 days following ChAdOx1 nCoV-19 vaccination should look for any combination of thrombocytopenia and elevated D-dimer, and/or low fibrinogen with a low threshold for requesting imaging of the appropriate organ, in particular, the brain central venous sinus and abdominal splanchnic venous systems for thrombosis plus anti-PF4 ELISA testing in consultation with haematology.

Main Lesson Box

- Vaccine-induced Immune Thrombotic Thrombocytopenia (VITT) is rare but potentially life-threatening
- This should be considered when patients present day 4-28 post vaccination with
 - unusual site thrombosis – splanchnic and/or central venous sinus thrombosis
 - Thrombocytopenia (or falling platelets) and markedly elevated D-dimer
- Specific testing to detect anti-PF4 antibody is needed to support VITT
- Treat with non-heparin anticoagulation, IVIG and consider pulsed methylprednisolone. Avoid platelet transfusions

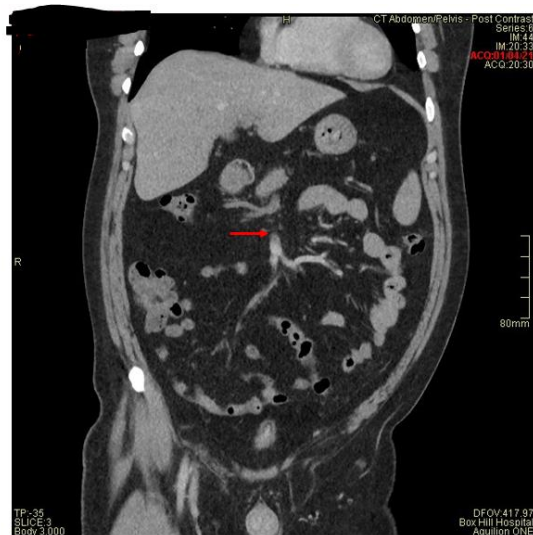

Figure 1a. CT-venogram at presentation showing filling defect of portal vein, contrast in superior mesenteric vein and its tributaries (red arrow, coronal plane)

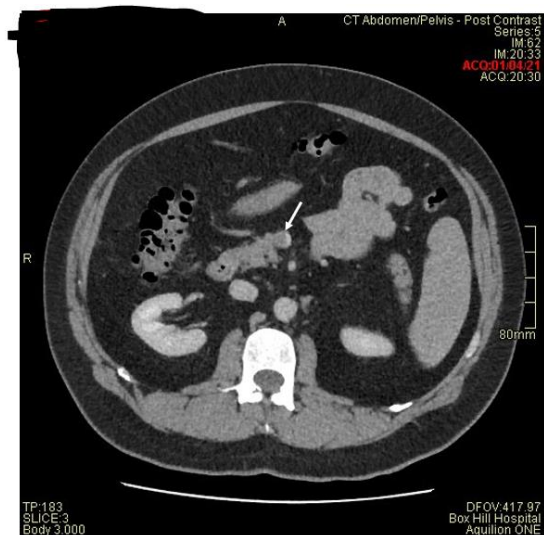


Figure 1b CT-venogram at presentation showing thrombus in superior mesenteric vein (white arrow shows contrast, axial plane)

References:

1. MHRA issues new advice, concluding a possible link between COVID-19 Vaccine AstraZeneca and extremely rare, unlikely to occur blood clots. [press release]. 7th April 2021 2021.
<https://www.gov.uk/government/news/mhra-issues-new-advice-concluding-a-possible-link-between-covid-19-vaccine-astrazeneca-and-extremely-rare-unlikely-to-occur-blood-clots>
2. Favaloro EJ, Mohammed S, Donikian D, et al. A multicentre assessment of contemporary laboratory assays for heparin induced thrombocytopenia. *Pathology*. 2021;53(2):247-56
3. Schultz NH, Sorvoll IH, Michelsen AE, et al. Thrombosis and Thrombocytopenia after ChAdOx1 nCoV-19 Vaccination. *N Engl J Med*. 2021.
4. Brodard J, Kremer Hovinga JA, Fontana P, et al. COVID-19 patients often show high-titer non-platelet-activating anti-PF4/heparin IgG antibodies. *J Thromb Haemost*. 2021.
5. Warkentin TE. High-dose intravenous immunoglobulin for the treatment and prevention of heparin-induced thrombocytopenia: a review. *Expert Rev Hematol*. 2019;12(8):685-98.