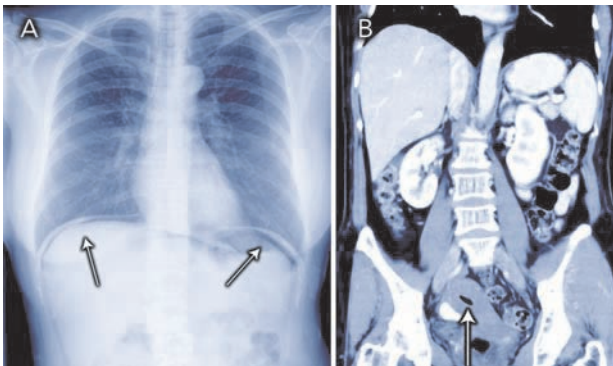


## Pneumoperitoneum: a non-surgical cause



A 53-year-old woman presented with a 2-day history of epigastric pain. She had mild tenderness over the right upper quadrant and epigastrium, with no peritonism. A chest x-ray revealed free gas under the diaphragm (Figure, A; arrows). A computed tomography scan confirmed a large pneumoperitoneum but no hollow-viscus perforation; the uterus was filled with gas (Figure, B; arrow). On further questioning, the patient recalled that the pain began after she sat on the gas outlet of a pneumatic spa. She was managed conservatively and discharged uneventfully. Air introduced through the gynaecological tract is a non-surgical cause of pneumoperitoneum. Distension of the uterus with gas on imaging can be a clue to diagnosis.

Yu Xuan Kitzing, Radiology Registrar

Sam McCormack, Radiologist

Department of Radiology, Royal Prince Alfred Hospital,  
Sydney, NSW.

liyuxu@rad.rpa.cs.nsw.gov.au

□