

## Spotted black snake (*Pseudechis guttatus*) envenoming

Melanie Jansen, Monique McLeod, Julian White and Geoffrey K Isbister

We report two cases of spotted black snake (*Pseudechis guttatus*) envenoming. One patient experienced localised burning pain around the bite and developed nausea, vomiting, diarrhoea, upper abdominal cramping and diaphoresis. He was treated with intravenous fluids and antiemetics, but no antivenom, and was discharged 23 hours after the bite. The second patient developed a severe headache, blurred vision and mild nausea, associated with severe pain and swelling of the bitten limb that took 4 days to resolve.

No antivenom was given and the patient had no sequelae. Neither patient developed significant coagulopathy, myolysis or neuromuscular paralysis. Bites by this species appear to cause effects similar to those of the more common red-bellied black snake (*P. porphyriacus*). (MJA 2007; 186: 41-42)

### Clinical record

#### Patient 1

A 47-year-old male farmer in the Upper Hunter region of New South Wales was bitten by a spotted black snake and developed non-specific systemic effects with localised pain and swelling. The snake came from under a bale of hay and bit him on the dorsal aspect of the right foot. He applied a 7.5 cm elastic bandage up to the knee within 5 minutes, and arrived at the local hospital asymptomatic. The patient had no significant past medical history and took no regular medications. The dead snake was identified as *Pseudechis guttatus* by G KI, using a key for identification.<sup>1</sup>

The patient was transferred to a larger hospital 2 hours and 20 minutes post-bite, and the first aid was reinforced. He had no abnormalities on examination. Thirty minutes after arrival, he developed burning pain around the bite, associated with nausea, vomiting, diarrhoea, upper abdominal cramping, and diaphoresis. This was treated with 10 mg intravenous metoclopramide and intravenous fluids. A snake venom detection kit swab from the bite site was positive in the black snake well. He had persistent vomiting, which was treated with 8 mg ondansetron.

He was transferred to a tertiary hospital intensive care unit 7 hours post-bite. The symptoms gradually resolved, except for ongoing pain at the bite site. The following morning, 15 hours post-bite, he was asymptomatic except for persistent pain in the foot. The pressure bandage was removed, with no immediate change in his condition. There was mild bruising around the bite site and evidence of a second bite. He also had right, tender inguinal lymphadenopathy. About 20 minutes after removal of the bandage, the pain in the right leg increased significantly and he was treated with oral opiate analgesia. Results of coagulation studies remained normal and his creatine kinase had a minor elevation to 348 IU/L (reference range, 50–200 IU/L) 17 hours post-bite. The patient remained well and was discharged 23 hours after the bite.

#### Patient 2

A 33-year-old amateur herpetologist was bitten on the left hand by a captive spotted black snake while cleaning the cage. Identification of the snake as *P. guttatus* was confirmed by JW. The patient immediately applied a local pressure bandage with no splint. Over an hour, he developed a severe frontal headache, blurred vision, mild nausea and dizziness, and presented to hospital about 2 hours post-bite. He appeared to have mild slurring of speech, but

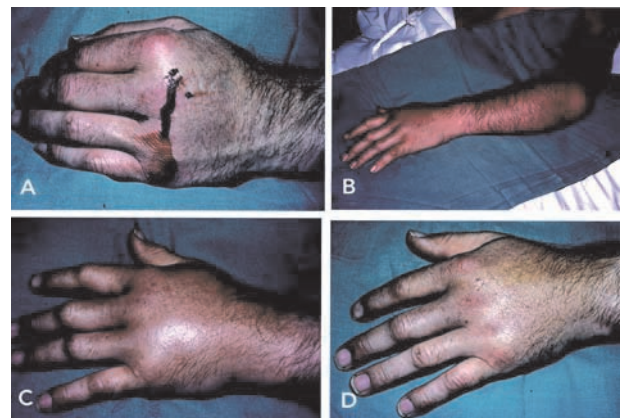
no ptosis or other signs of neurotoxic envenoming. The bitten hand was very painful, with swelling and slight bruising (Box 1A).

He was treated with intravenous fluids and analgesia, but no antivenom. Results of laboratory tests on admission were normal, except for the activated partial thromboplastin time, which was marginally elevated (41 seconds; reference range, 25–40 seconds). The following day, 13 hours post-bite, he had a persistent headache, mild nausea and severe pain in the bitten hand. Although the systemic symptoms resolved over 12 hours, the bitten hand remained painful and swollen, requiring parenteral opiate analgesia. Forty-eight hours post-bite, the pain and swelling extended to the left elbow (Box 1B,C), with axillary adenopathy. He was treated with intravenous flucloxacillin and seen by the surgical team. Compartment pressures were within the normal range and no surgical intervention occurred. Four days post-bite, the pain and swelling were subsiding significantly (Box 1D). He was discharged on oral flucloxacillin and recovered over several days.

### Discussion

Black snakes are found throughout Australia, with mulga snakes (*Pseudechis australis*) occurring across most of the mainland except

#### 1 Local and regional effects of the bite in Patient 2



A: The hand 3 hours post-bite. B: The forearm 48 hours post-bite. C: The hand 48 hours post-bite. D: The hand 4 days post-bite. Original photo copyright Dr Julian White.

## 2 Spotted brown colour phase of spotted or blue-bellied black snake, *Pseudechis guttatus*



Original photo copyright Dr Julian White. ◆

the east coast.<sup>2,3</sup> In the east, the most common is the red-bellied black snake (*P. porphyriacus*), and most of the human population in this area will have encountered this snake at some stage. The spotted black snake or blue-bellied black snake (*P. guttatus*; Box 2) is less common, and primarily inhabits south-east Queensland and inland northern NSW.<sup>2,3</sup>

These cases suggest that spotted black snake bites are similar in effects to red-bellied black snake bites,<sup>2-4</sup> including generalised systemic features and local effects, such as marked swelling and pain at the bite site. They were not similar to the more severe effects of mulga snakes<sup>3,5</sup> and Collett's snake (*P. colletti*),<sup>6</sup> characterised by myotoxicity, anticoagulant coagulopathy and secondary renal impairment. The limited number of cases does not exclude the possibility that spotted black snake bite does occasionally cause significant myolysis like that from red-bellied black snake bite. Serial creatine kinase measurements should be done in all cases of spotted black snake bite with systemic envenoming.

There is only one previous report of a bite by a juvenile spotted black snake.<sup>7</sup> In that case, localised necrosis at the bite site was treated with surgical debridement. However, the report only included photographs and little further information. Animal studies have demonstrated that spotted black snake venom is both neurotoxic and myotoxic,<sup>8,9</sup> and both effects are neutralised by black and tiger snake antivenoms. However, neither of our patients had any evidence of significant neurotoxicity or myotoxicity that may be expected from in-vitro studies.

Neither patient was given antivenom, because there was no evidence of major systemic envenoming. As with red-bellied black snake envenoming, antivenom is only used when non-specific systemic effects do not respond to symptomatic treatment. It could be argued that, for Patient 1, who had ongoing vomiting, antivenom might have significantly reduced symptoms and resolved the vomiting, as it can do with red-bellied black snake bites. However, the vomiting responded to ondansetron, and use of antivenom always carries a risk of an allergic reaction.

Although antibiotics were used in the second patient, the extensive local pain and swelling are more likely to be due to local venom effects and tissue reaction, also seen with red-bellied black snakes.<sup>4</sup>

### Acknowledgements

Geoff Isbister is supported by a National Health and Medical Research Council (NHMRC) Clinical Career Development Award ID300785.

### Competing interests

Julian White is employed by the Women's and Children's Hospital, Adelaide, which is paid by CSL Ltd to provide a consultant clinical toxicology service for users of CSL antivenom and venom detection products.

### Author details

Melanie Jansen, Medical Student<sup>1</sup>

Monique McLeod, Medical Student<sup>1</sup>

Julian White, MB BS, MD, Associate Professor,<sup>2</sup> Consultant Clinical Toxicologist, Head of Toxicology<sup>3</sup>

Geoffrey K Isbister, BSc, FACEM, MD, Senior Research Fellow,<sup>4</sup> Clinical Toxicologist,<sup>5</sup> Consultant Toxicologist<sup>6</sup>

1 School of Medical Practice and Population Health, University of Newcastle, Newcastle, NSW.

2 Faculty of Health Sciences, University of Adelaide, Adelaide, SA.

3 Women's and Children's Hospital, Adelaide, SA.

4 Tropical Toxicology Unit, Menzies School of Health Research, Charles Darwin University, Darwin, NT.

5 NSW Poison Information Centre, The Children's Hospital at Westmead, Sydney, NSW.

6 Department of Clinical Toxicology, Newcastle Mater Hospital, Newcastle, NSW.

Correspondence: [gsbite@ferntree.com](mailto:gsbite@ferntree.com)

### References

- 1 Cogger HG. Reptiles and amphibians of Australia. 6th ed. Port Melbourne: Reed Books Australia, 2000.
- 2 Sutherland SK, Tibballs J. Australian animal toxins. 2nd ed. Melbourne: Oxford University Press, 2001.
- 3 White J. Clinical toxicology of snakebite in Australia and New Guinea. In: Handbook of clinical toxicology of animal venoms and poisons. New York: CRC Press, 1995: 595-618.
- 4 Pearn J, McGuire B, McGuire L. The envenomation syndrome caused by the Australian red-bellied black snake *Pseudechis porphyriacus*. *Toxicon* 2000; 38: 1715-1729.
- 5 Currie BJ. Snakebite in tropical Australia: a prospective study in the "Top End" of the Northern Territory. *Med J Aust* 2004; 181: 693-697.
- 6 Isbister GK, Hooper MR, Dowsett R, et al. Collett's snake (*Pseudechis colletti*) envenoming in snake handlers. *QJM* 2006; 99: 109-115.
- 7 Williams D. *Pseudechis guttatus* envenomation photographs. <http://www.kingsnake.com/aho/pdf/menu6/guttatus.pdf> (accessed Apr 2006).
- 8 Ramasamy S, Fry BG, Hodgson WC. Neurotoxic effects of venoms from seven species of Australasian black snakes (*Pseudechis*): efficacy of black and tiger snake antivenoms. *Clin Exp Pharmacol Physiol* 2005; 32: 7-12.
- 9 Ramasamy S, Isbister GK, Hodgson WC. The efficacy of two antivenoms against the in vitro myotoxic effects of black snake (*Pseudechis*) venoms in the chick biventer cervicis nerve-muscle preparation. *Toxicon* 2004; 44: 837-845.

(Received 26 Jul 2006, accepted 9 Oct 2006)

□