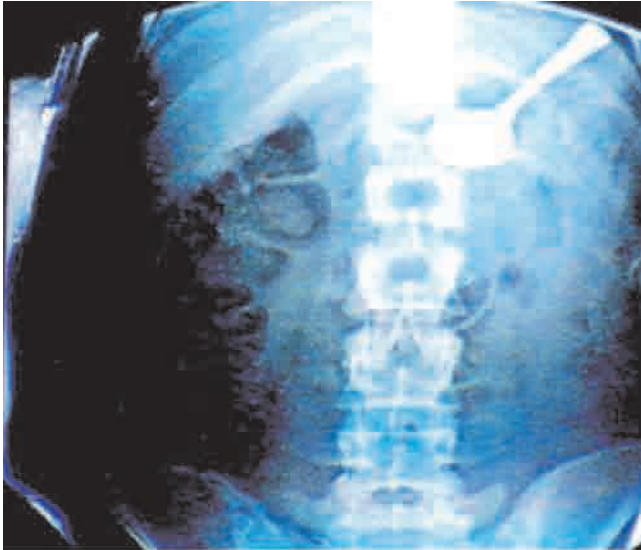
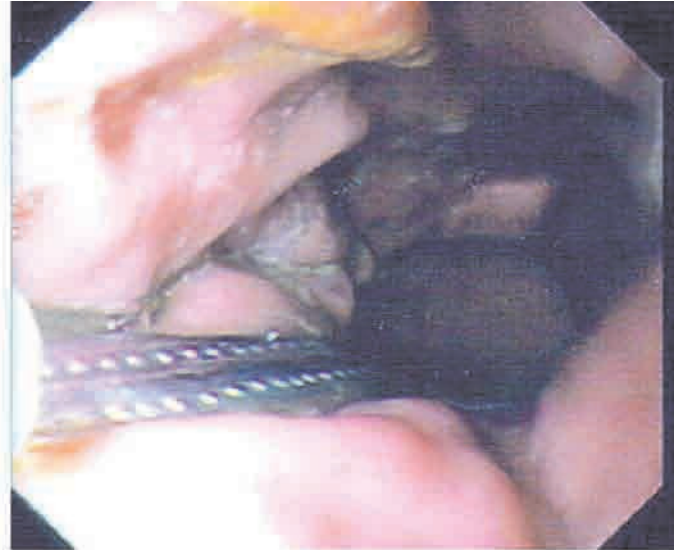


CHRISTMAS OFFERINGS

No laughing matter



Radiograph showing the position of the spoon in the stomach.



The gastroscope view of the spoon in the stomach.

A 26-year-old woman accidentally swallowed a 15 cm long spoon during a "laughing attack". The spoon was removed from the stomach with a single lumen gastroscope (with great difficulty).

Bernard R Beldholm, MB BS, Advanced Trainee in General Surgery
Alice U Lee, MB BS, FRACP, PhD, Gastroenterologist
Canterbury Hospital, Sydney, NSW.
Correspondence: beldholm@yahoo.com