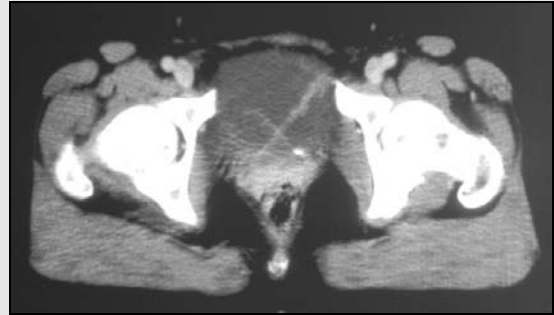


snapshot

X marks the spot

COMPUTED TOMOGRAPHY (CT) scan of the abdomen and pelvis was performed for staging of prostatic carcinoma in a 50-year-old man. The “X” is formed by the two ureteric jets in the bladder in this intravenous contrast-enhanced CT of the pelvis.



David C Wong

Radiologist, Wesley Hospital
Auchenflower, QLD