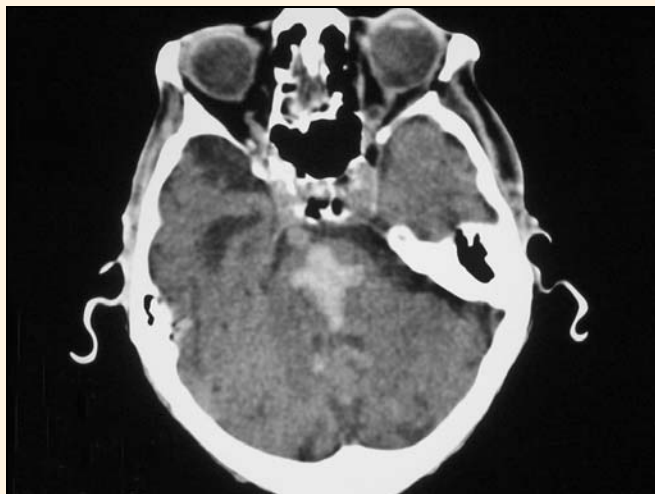

Divine intervention

FREQUENTLY, I call on colleagues for help with a radiological diagnosis. This time I received assistance from a higher authority!

The image is a non-contrast axial computed tomography scan of the brain, showing haemorrhage into the central pons.

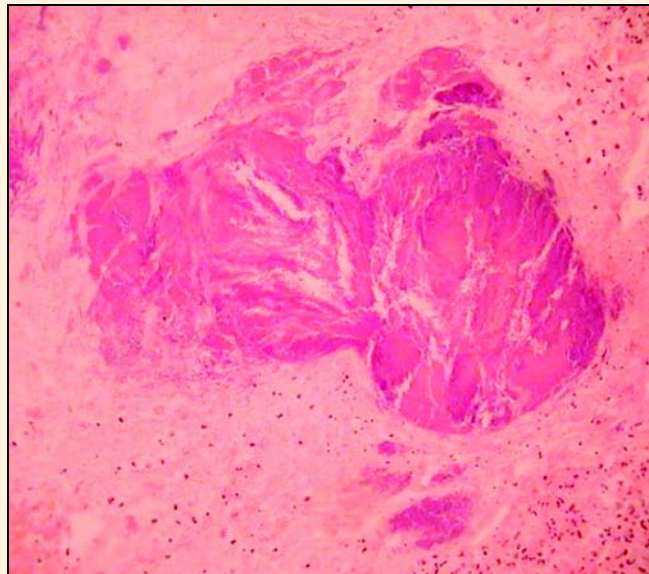


Chris J O'Donnell

Director of Radiology, Frankston Hospital
Frankston, VIC

The Land from Down Under

WE RECEIVED AN APPENDIX in our anatomical pathology laboratory and were struck by the resemblance of the luminal contents to our wide brown land.



Alison M Skene,* Alastair J Veitch,† Piero L Nelva‡

* Anatomical Pathologist, † Anatomical Pathologist, ‡ Medical Scientist
Anatomical Pathology, Southern Cross Pathology Australia, Clayton, VIC